

Chronic Rupture of the Achilles Tendon: A New Technique of Repair*†

BY ROGER A. MANN, M.D.‡, GEORGE B. HOLMES, JR., M.D.§, KAREN S. SEALE, M.D.¶,
AND DAVID N. COLLINS, M.D.#, PHILADELPHIA, PENNSYLVANIA

From the Department of Orthopaedic Surgery, Jefferson Medical College, Thomas Jefferson University, Philadelphia

ABSTRACT: A new operative technique is described for the treatment of patients who have a rupture of the Achilles tendon. The large gap between the proximal and distal stumps of the Achilles tendon in seven patients was bridged by use of the tendon of the flexor digitorum longus as the graft. At the most recent follow-up examination (average follow-up, thirty-nine months; range, two to six years), the result was excellent or good in six patients and fair in one. Postoperatively, two patients needed an adjuvant procedure: one, a local rotation flap and the other, a split-thickness skin graft. Both patients had excellent restoration of function. The patient who had a fair result had a persistent limp and residual discomfort. There were no re-ruptures.

Patients who have a rupture of the Achilles tendon commonly are seen immediately after the rupture. The merits of non-operative and operative management of an acute rupture of this tendon have been well described^{1-5,7}. However, the technique of primary anastomosis¹⁰ is sometimes inadequate for neglected or undiagnosed ruptures. In those patients, the delay in treatment leads to the development of a large gap between the proximal and distal portions of the ruptured tendon or between the avulsed end of the tendon and the posterosuperior surface of the calcaneus. Then, an autogenous graft or synthetic intercalary material must be used to bridge the gap.

There are several potential ways to span the gap in the patient who has a chronic rupture^{2,4,8,9,11,12,14,15}. Some authors have turned down a strip of the tendon or have bridged the defect with a graft of fascia lata². Others have recommended transfer of the peroneus brevis^{14,15}, the plantaris^{9,12}, or the posterior tibial tendon¹¹. Synthetic materials, such as carbon fiber or Dacron polyester, also have been used as a scaffold

for the formation of the scar of repair^{6,8}.

We describe a technique, developed by the senior one of us (R. A. M.), in which the flexor digitorum longus is used to repair the ruptured Achilles tendon.

Materials and Methods

From January 1985 through October 1988, seven patients who had a long-standing rupture of the Achilles tendon were treated with the operative technique to be described. There were three women and four men, and the ages ranged from thirty-three to sixty-six years; all but one patient was older than fifty-four years (Table I). The duration of follow-up ranged from two to six years. Three patients (Cases 1, 3, and 4) had a history of previous injections of steroid about the Achilles tendon by other physicians for presumed tendinitis. One patient (Case 4) had had four injections and the other two patients, at least two. Due to the chronicity and variability of the patients' complaints, it was difficult to ascertain whether the injections had preceded or had hastened the rupture. One patient (Case 2) was diabetic and morbidly obese. Hypertension was present in three patients (Cases 1, 5, and 7).

The duration of the symptoms ranged from three to thirty-six months. Two patients (Cases 3 and 5) had no history of specific trauma prior to the onset of symptoms, but had a gradual onset of pain and difficulty in walking. Of the other five patients, two had sustained a blow to the heel, one had fallen while hiking, one had a dorsiflexion injury, and one had fallen down stairs (Table I).

Because of the chronicity of the symptoms, no patient had the ecchymosis, swelling, and point tenderness that are commonly associated with an acute rupture. There was only modest swelling and edema about the posterior aspect of the ankle, but all patients had major weakness of active plantar flexion and a limp. In five patients, the defect in the Achilles tendon was visible or palpable, and in one patient (Case 4), the defect had been filled with scar tissue. Usually, there was some tenderness about the proximal and distal stumps of the ruptured tendon. The Thompson test was positive in all patients (that is, squeezing of the calf did not result in plantar flexion of the foot).

Three patients (Cases 2, 4, and 5) had changes on the plain radiographs that were helpful in confirming the diagnosis of rupture. The one diagnostic clue that was common to these three patients was the presence of calcification

* No benefits in any form have been received or will be received from a commercial party related directly or indirectly to the subject of this article. No funds were received in support of this study.

† Read at the meeting of the British Orthopaedic Foot Surgery Society, Liverpool, England, November 23, 1990.

‡ Department of Orthopaedic Surgery, University of California School of Medicine, Suite 1200, 3300 Webster Street, Oakland, California 94609.

§ Department of Orthopaedic Surgery, Jefferson Medical College, Thomas Jefferson University, 501 Curtis Building, 1015 Walnut Street, Philadelphia, Pennsylvania 19107.

¶ 3409 Ridge Pass Court, Little Rock, Arkansas 72207.

Suite 400, 500 South University, Little Rock, Arkansas 72205.

TABLE I
CLINICAL DATA AND RESULTS

Case	Sex, Age (Yrs.)	Mechanism of Injury	Length of Gap* (cm)	Duration of Symptoms (Mos.)	Duration of Follow-up (Mos.)	Result
1	M, 58	Fall while hiking	3	36	72	Excellent
2	F, 58	Blow to the heel	2-3	12	36	Excellent
3	F, 54	Stumbled at home	3	11	36	Fair
4	M, 65	Dorsiflexion injury	3	12	40	Excellent
5	F, 63	While walking	7	14	24	Good
6	M, 33	Blow to the heel	NA	3	40	Excellent
7	M, 66	Fall down stairs	NA	6	25	Good

* NA = not available.

in the distal portion of the proximal stump of the Achilles tendon (Fig. 1).

Operative Technique

The procedure was performed with the patient prone and under general or spinal anesthesia, with use of tourniquet control. We used a hockey-stick-shaped incision starting proximally, medial to the tendon. The incision was continued distally and then gently curved laterally, distal to the insertion of the tendon (Fig. 2). The length of the incision was eight to ten centimeters, depending on the exposure necessary to see the lesion completely and to execute the repair.

The tendon sheath was opened at the site of the rupture, and the location and characteristics of the rupture were assessed. The rupture was classified as either a mid-substance tear or an avulsion.

A second seven-centimeter incision was then made, starting on the medial aspect of the foot, slightly inferior and distal to the navicular bone and extending along the upper border of the abductor hallucis toward the first metatarsophalangeal joint (Fig. 2). Dissection was done dorsal to the abductor hallucis, allowing the muscle to be retracted plantarward, and the flexor hallucis brevis and the tendons of the flexor hallucis longus and flexor digitorum longus were identified. Visualization of these tendons was enhanced by the release of the knot of Henry³, which occupied the proximal portion of the incision. It was crucial to show the location of the digital branches of the flexor digitorum longus during the dissection (Fig. 3). The tendon of the flexor digitorum longus was then cut just proximal to its division, into separate digital branches. We routinely sutured the proximal aspect of the distal stump of the flexor digitorum longus tendon to the adjacent intact flexor hallucis longus tendon (Fig. 4). The lesser toes were held with the interphalangeal joints in neutral extension, so that the anastomosis was not under tension. The proximal part of the flexor digitorum longus tendon was then pulled back into the proximal part of the wound, lateral and posterior to the neurovascular bundle, and its sheath was freed to allow it to be placed adjacent to the Achilles tendon.

A transverse hole was drilled through the posterior

aspect of the calcaneus, and, with the foot held in approximately 10 to 15 degrees of plantar flexion, the tendon of the flexor digitorum longus was passed through the drill-hole in a medial-to-lateral direction and was sutured to itself with a non-absorbable suture (Fig. 5). A central slip from the proximal portion of the Achilles tendon was mobilized and brought down to the distal stump or into a trough created in the calcaneus just anterior to the original insertion of the Achilles tendon (Figs. 6-A and 6-B). This spanned the gap between the end of the Achilles tendon and the calcaneus. The slip was then cross sutured to the flexor digitorum

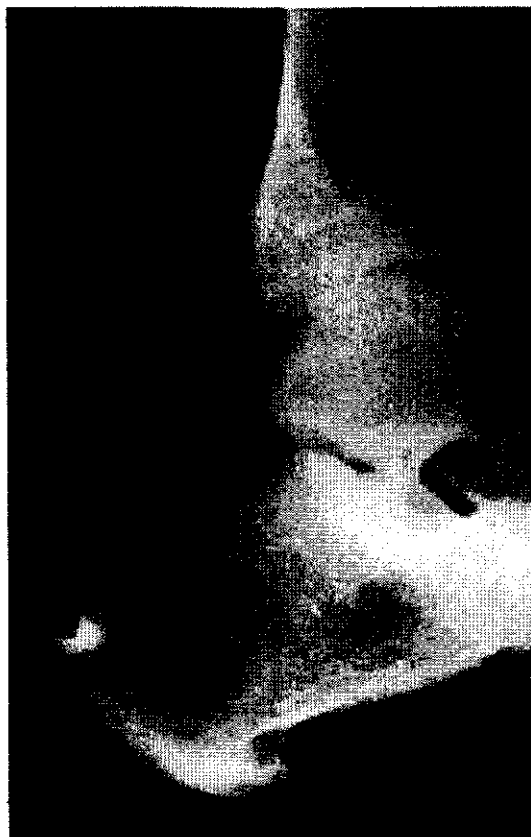

FIG. 1

Radiograph showing a proximally displaced calcification in the distal portion of the proximal stump of the Achilles tendon.

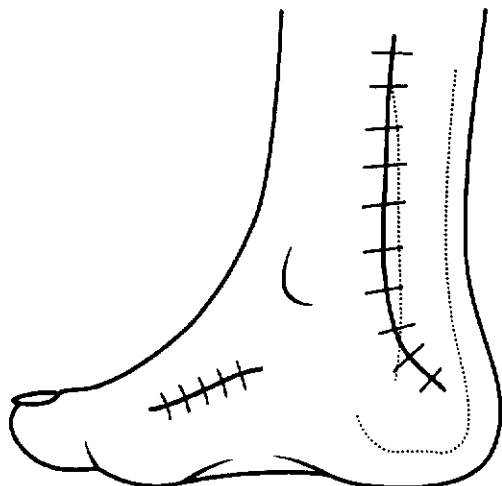


FIG. 2

Figs. 2 through 6-B: Operative technique.
 Fig. 2: Drawing showing the incisions used for exploration of the site of the rupture and for harvest of the flexor digitorum longus tendon. Medial view.

duced to approximately 5 degrees, followed by an additional four weeks of immobilization. Weight-bearing in a below-the-knee cast was permitted about eight weeks after the operation. The foot was then placed in a removable brace, supplemented by a heel-lift, for another three months. Range-of-motion and strengthening exercises were initiated at this time. Athletic activities were restricted for five to six months after the operative reconstruction.

Operative Findings

On exploration, there was gross discontinuity of the tendon in five patients, while in two (Cases 2 and 4), the discontinuity was caused by an avulsion of the insertion of the tendon. In both of these patients, the proximal calcification was confirmed by discontinuity and scarring of the tendon, which intervened between the calcification and the superior border of the calcaneus. In one patient (Case 3), an extensive area of scar at the insertion of the Achilles tendon was consistent with the patient's history of an earlier excision of a spur and of injections of steroid for chronic

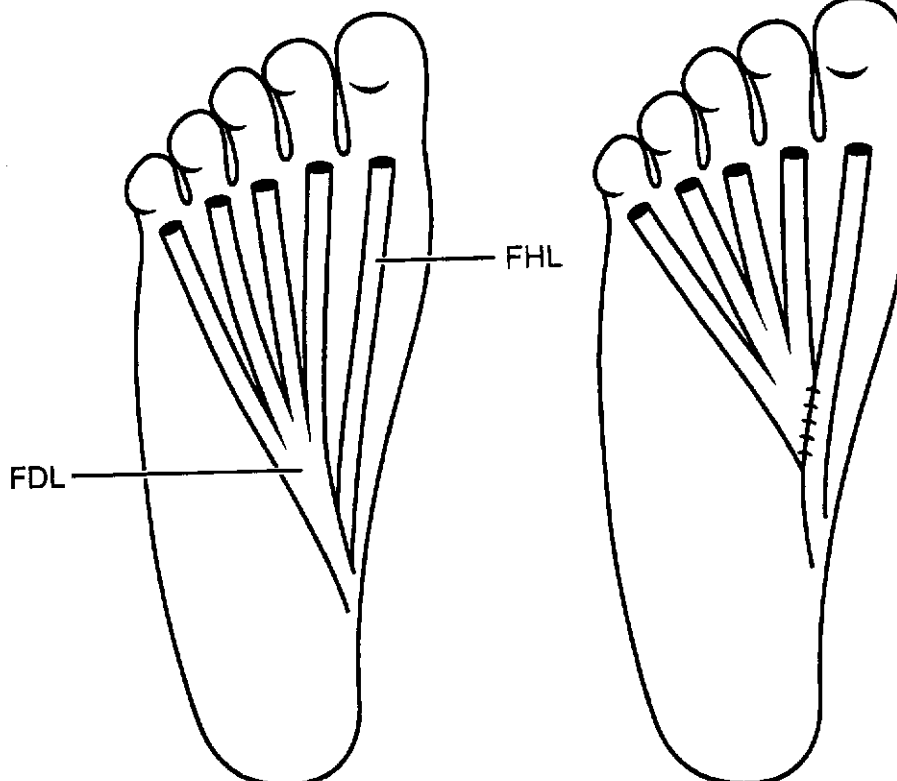


FIG. 3

FIG. 4

Fig. 3: Plantar view of the flexor digitorum longus (FDL) tendon and the adjacent flexor hallucis longus (FHL) tendon.
 Fig. 4: Anastomosis of the distal stump of the flexor digitorum tendon to the flexor hallucis longus tendon.

longus tendon. When length allowed, the proximal stump of the Achilles tendon was reattached to the calcaneus with a pull-out wire technique.

Postoperatively, the foot was placed in approximately 10 degrees of equinus angulation in a below-the-knee non-weight-bearing cast. At four weeks, the angulation was re-

pain. One patient (Case 2) had thickening of the segment of tendon for five centimeters proximal to its insertion, with loss of the normal parallel orientation of tendinous fibers. In two patients (Cases 6 and 7), there was a large gap in the substance of the distal aspect of the tendon but no radiographic evidence of calcification.

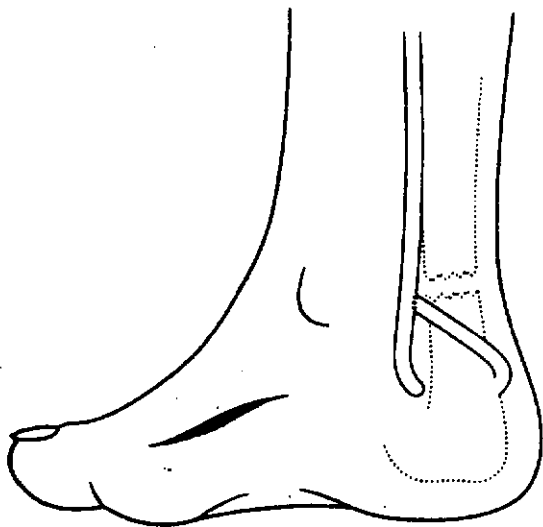


FIG. 5

The flexor digitorum longus is pulled through a transverse drill-hole in the calcaneus.

Results

The final result in four patients was excellent. These patients had no pain, limitation of activities, or postoperative complications of the wound. They had normal dorsiflexion and excellent strength with independent tip-toe stance.

Two patients (Cases 5 and 7) had a good result. They were pain-free and had at least neutral dorsiflexion, but there was a functional decrease in strength, inability to return to pre-injury activities, or postoperative problems with the wound. One patient (Case 5) needed a local rotation flap for an area of necrosis of the wound. However, within seven months of the repair, she was pain-free, walked without a limp, and had returned to pre-injury activities. The other patient (Case 7) needed a split-thickness skin graft. She also eventually returned to pre-injury activities without pain, but she had a slight functional decrease in strength of the involved side.

One patient (Case 3) had a fair result, with some residual intermittent pain and weakness (limp), but she returned to activities of daily living without walking aids.

No patient had a poor result. All patients retained active flexion of the lesser toes, and there were no subsequent hammer-toe deformities. There were no re-ruptures.

Return of function was observed in all patients. Only two of the seven patients had been athletically active previously, and all but Case 3 returned to the previous level of activity. All patients walked without any assistive devices. Dorsiflexion at least to neutral and normal plantar flexion were obtained in all patients.

Discussion

The management of acute ruptures of the Achilles tendon remains controversial. However, patients who have a chronic rupture need operative intervention in order to obtain an optimum result. These patients commonly have a history of several months or even years of pain and weakness, and there is generally a large gap between the ruptured portions of the tendon. Simple immobilization of the ankle in equinus angulation will not minimize the gap sufficiently for effective healing. Standard techniques of primary anastomosis will also be inadequate to bring the ends of the tendon together. Supplementary materials, such as autogenous grafts, allografts, or synthetic materials, must be used to span the defect and re-establish the functional integrity of the Achilles tendon.

The choice of the flexor digitorum longus as the supplementary material has certain theoretical advantages. The use of an autogenous source avoids the problems of host rejection that are associated with the use of an allograft or a synthetic material. Several of the autogenous substitutes that have been advocated, such as free fascia and turn-down fascial grafts, are essentially avascular and theoretically must be revascularized to be incorporated into the repair. The transfer of the flexor digitorum longus uses a viable

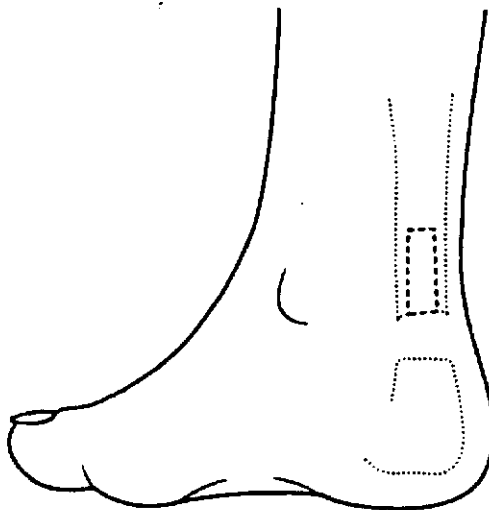


FIG. 6-A

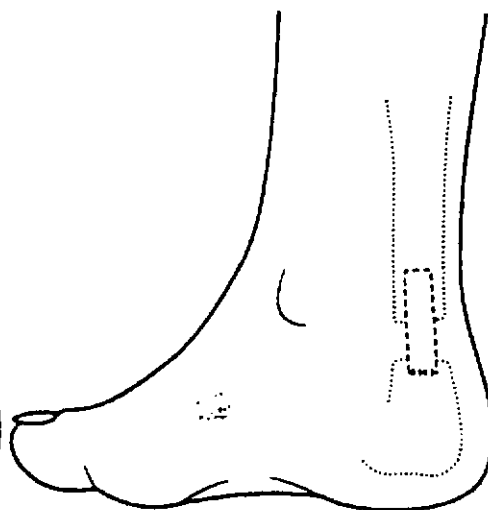


FIG. 6-B

Fig. 6-A: A central slip is created from the proximal portion of the Achilles tendon.
Fig. 6-B: The central slip is mobilized distally to the superior aspect of the calcaneus.

ditional
below-
fter the
e brace,
months.
initiated
ve to six

y of the
(4), the
rtion of
calcifi-
g of the
and the
Case 3),
Achilles
n earlier
chronic

segment
ion, with
is fibers.
e gap in
at no ra-

tendon structure with an intact vascular supply, and the biomechanical characteristics of the donor material are similar to those of the recipient.

Other tendons have been used for reconstruction of the Achilles tendon. Use of the peroneus brevis has the theoretical disadvantage that eversion will be weakened. However, this specific outcome has yet to be described in the literature, to our knowledge. In one technique of transfer of the peroneus¹⁵, the tendon is placed through the distal stump of the Achilles tendon in a lateral-to-medial direction, but this fails to duplicate the more medial pull of the normal Achilles tendon. In contrast, with our technique the tendon is transferred directly into the calcaneus through a drill-hole from medial to lateral, and this construct more closely simulates the actual pull of the normal tendon. It also affords the optimum opportunity for revascularization of the distal end of the tendon and its firm incorporation at the site of attachment. Use of the flexor digitorum longus does not have the hypothetical disadvantage of disrupting the balance between the evertors (the peroneus brevis and peroneus longus tendons) and the principal invertor (the posterior tibial tendon).

Transfer of the flexor digitorum longus allows retention of one of its functions as a plantar flexor of the foot. Since the over-all strength for plantar flexion of the foot that is contributed by the flexor digitorum longus is minor compared with that of the gastrocnemius-soleus complex, it cannot, by itself, completely replace the motor strength of the gastrocnemius-soleus complex. Its contribution theoretically must supplement that obtained by the reconstruction of the gastrocnemius-soleus complex as part of the procedure described earlier.

In contrast to the flexor digitorum longus, which is only a flexor, the peroneus brevis is one of the two evertors of the foot. The total strength (per cent of the total force acting on the ankle) of the peroneus longus and brevis is 7.1 per cent, with the peroneus brevis alone accounting for 2.6 per cent¹³. This is balanced by the primary invertor of the subtalar joint, the posterior tibial muscle, which has a strength of 6.4 per cent¹³. Therefore, the use of the peroneus brevis in a transfer carries the risk of changing the balance between the evertors and invertors of the foot.

The potential loss of power of flexion of the lesser toes

can be managed in two ways. Since the flexor digitorum longus is harvested from the plantar aspect of the foot just proximal to the point where it separates into the digital branches, its proximity to the flexor hallucis longus tendon can be used to facilitate suture of the distal stump of the flexor digitorum to the adjacent flexor hallucis longus. This allows for retention of the power of the digital flexors, although only in unison with the flexor hallucis longus. An alternative is simply to let the distal stump of the flexor digitorum longus go free. This may be preferable in patients who have a major, pre-existing, flexible hammer-toe deformity. Some of the strength of the digital flexors will be retained because of the intrinsic flexors.

Two patients needed a secondary soft-tissue procedure due to superficial necrosis of the wound. The presence of hypertension in these patients was a contributing factor. Additionally, one of them had a history of local injections of cortisone. Advanced age, systemic metabolic disease, and local injections of cortisone in the presence of an extensive dissection in these patients highlight the need for meticulous dissection, maintenance of thick skin flaps, and delicate handling of soft tissues. However, despite the superficial skin problems in these two patients, the integrity of the repair with the flexor digitorum longus tendon was not compromised during the secondary procedure for soft-tissue coverage.

No re-ruptures were noted in the current series, at an average duration of follow-up of thirty-nine months. Nistor reported two re-ruptures, twelve and thirteen months after repair of an acute rupture in forty-four patients. Inglis et al. reported re-rupture after repair in nine of twenty-three patients; the re-rupture usually occurred within two months after the removal of immobilization.

The results of our study indicate that transfer of the tendon of the flexor digitorum longus is an effective and durable operation for reconstruction of the Achilles tendon in patients in whom the rupture has been neglected or treatment has failed. The indications for this procedure may also be extended to patients who have a massive, acute rupture in which it is not possible to bridge the defect by primary anastomosis alone. The restoration of function and the satisfaction of the patient are further supported by the theoretical advantages of use of the flexor digitorum longus.

References

1. ARNER, ORED, and LINDHOLM, ÅKE: Subcutaneous Rupture of the Achilles Tendon. A Study of 92 Cases. *Acta Chir. Scandinavica, Supplementum* 239, 1959.
2. BUGG, E. I., JR., and BOYD, B. M.: Repair of Neglected Rupture or Laceration of the Achilles Tendon. *Clin. Orthop.*, 56: 73-75, 1968.
3. HOPPENFELD, STANLEY, and DEBOER, PIET [EDITORS]: *Surgical Exposures in Orthopaedics: The Anatomic Approach*, p. 508. Philadelphia, J. B. Lippincott, 1984.
4. HOWARD, C. B.; WINSTON, I.; BELL, W.; MACKIE, I.; and JENKINS, D. H. R.: Late Repair of the Calcaneal Tendon with Carbon Fibre. *J. Bone and Joint Surg.*, 66-B(2): 206-208, 1984.
5. INGLIS, A. E.; SCOTT, W. N.; SCULCO, T. P.; and PATTERSON, A. H.: Ruptures of the Tendo Achillis. An Objective Assessment of Surgical and Non-Surgical Treatment. *J. Bone and Joint Surg.*, 58-A: 990-993, Oct. 1976.
6. JACOBS, D.; MARTENS, M.; VAN AUDEKERCKE, R.; MULIER, J. C.; and MULIER, F.: Comparison of Conservative and Operative Treatment of Achilles Tendon Rupture. *Am. J. Sports Med.*, 6: 107-111, 1978.
7. LEA, R. B., and SMITH, LYMAN: Non-Surgical Treatment of Tendo Achillis Rupture. *J. Bone and Joint Surg.*, 54-A: 1398-1407, Oct. 1972.
8. LEVY, M.; VELKES, S.; GOLDSTEIN, J.; and ROSNER, M.: A Method of Repair for Achilles Tendon Ruptures without Cast Immobilization. Preliminary Report. *Clin. Orthop.*, 187: 199-204, 1984.
9. LYNN, T. A.: Repair of the Torn Achilles Tendon, Using the Plantaris Tendon As a Reinforcing Membrane. *J. Bone and Joint Surg.*, 48-A: 268-272, March 1966.
10. NISTOR, LARS: Surgical and Non-Surgical Treatment of Achilles Tendon Rupture. A Prospective Randomized Study. *J. Bone and Joint Surg.*, 63-A: 394-399, March 1981.

11. PLATT, HARRY: Observations on Some Tendon Ruptures. *British Med. J.*, **1**: 611-615, 1931.
12. SCHEDL, RUDOLF, and FASOL, PAUL: Achilles Tendon Repair with the Plantaris Tendon Compared with Repair Using Polyglycol Threads. *J. Trauma*, **19**: 189-194, 1979.
13. SILVER, R. L.; DE LA GARZA, J.; and RANG, M.: The Myth of Muscle Balance. A Study of Relative Strengths and Excursions of Normal Muscles about the Foot and Ankle. *J. Bone and Joint Surg.*, **67-B**(3): 432-437, 1985.
14. TEUFFER, A. P.: Traumatic Rupture of the Achilles Tendon. Reconstruction by Transplant and Graft Using the Lateral Peroneus Brevis. *Orthop. Clin. North America*, **5**: 89-93, 1974.
15. TURCO, V. J., and SPINELLA, A. J.: Achilles Tendon Ruptures — Peroneus Brevis Transfer. *Foot and Ankle*, **7**: 253-259, 1987.

Copyright 1991 by The Journal of Bone and Joint Surgery, Incorporated

Treatment of de Quervain Tenosynovitis

A PROSPECTIVE STUDY OF THE RESULTS OF INJECTION OF STEROIDS AND IMMOBILIZATION IN A SPLINT*

BY JOHAN WITT, F.R.C.S.†, GARY PESS, M.D.†, AND RICHARD H. GELBERMAN, M.D.†, BOSTON, MASSACHUSETTS

From the Department of Orthopaedic Surgery, Massachusetts General Hospital, Boston

ABSTRACT: In a prospective study of non-operative treatment of de Quervain tenosynovitis, ninety-nine wrists of ninety-five consecutively seen patients who had this diagnosis had an injection of one milliliter of a 1 per cent lidocaine solution and one milliliter of a suspension containing forty milligrams of methylprednisolone acetate. Twelve patients (twelve wrists) were lost to follow-up. Of the remaining eighty-seven wrists, fifty-four (62 per cent) had a satisfactory outcome at a mean of eighteen months (minimum follow-up, twelve months). The duration of symptoms before treatment did not affect the outcome.

The result in thirty-three wrists (38 per cent) was considered unsatisfactory. Thirty of these wrists were subsequently treated with operative release of the first dorsal compartment, and twenty-two (73 per cent) of the thirty were found to have a separate compartment for the extensor pollicis brevis. The prevalence of a separate compartment is significantly higher than that in the general population, as shown in anatomical studies of cadavera.

Since its original description by de Quervain in 1895, stenosing tenosynovitis at the radial styloid process has been treated with a variety of methods. Commonly used non-operative techniques include immobilization of the wrist and thumb in a splint or cast and injection of steroids and local anesthetics into the first dorsal compartment. Although the results of non-operative treatment have been reported^{1,2,6,7,9,12-14}, we know of no prospective trial that included

an adequate number of patients and sufficiently long follow-up for definitive conclusions to be drawn. We undertook this study to determine the role of injection of steroids and immobilization in a splint in the management of patients who have de Quervain stenosing tenosynovitis.

Materials and Methods

Beginning in November 1986, ninety-five consecutively seen patients who had ninety-nine involved wrists were included in a prospective study of the treatment of de Quervain tenosynovitis with injection of steroids and immobilization in a splint. Twelve patients (twelve wrists) were lost to follow-up, leaving eighty-three patients who had eighty-seven involved wrists. The minimum duration of follow-up was twelve months. All patients were examined clinically by one of the three of us.

Sixty-four patients (77 per cent) were female and nineteen (23 per cent) were male. In forty-eight patients (58 per cent), the right wrist was involved and in thirty-nine patients (47 per cent), the left wrist was involved. Fifty (57 per cent) of the wrists were on the dominant side and thirty-seven (43 per cent), on the non-dominant side. The average age of the patients was forty-four years (range, sixteen to seventy-five years). The average duration of follow-up was eighteen months (range, twelve to thirty months), after exclusion of the patients in whom non-operative treatment failed and an operative release was done.

The occupations of the patients were housekeeping (twenty-six), secretarial and clerical work (seventeen), light manual labor (sixteen), managerial or professional work (sixteen), strenuous manual labor (four), music (two), and education (two). In twenty-one patients, the onset of pain was related to a specific traumatic event: a fall in eight, a fracture of the distal part of the radius in seven, trauma to the radial aspect of the wrist in three, and delivery of a child in three.

* No benefits in any form have been received or will be received from a commercial party related directly or indirectly to the subject of this article. No funds were received in support of this study.

† Department of Orthopaedic Surgery, Massachusetts General Hospital, Boston, Massachusetts 02114. Please address requests for reprints to Dr. Gelberman.